

Pictorial Essay of Lower Limb Giant Cell Tumour

Dr.Kishan Ashok Bhagwat¹, Dr.Shashikiran B R², Dr.Krishnarjun P²,
Dr.Bharath M jain², Dr.Reddy priyatham tulasi², Dr.Naveen Kumar²

¹Associate Professor, Department of Radiology, SSIMS & RC, Davangere, Karnataka, India.

²Postgraduate student, Department of Radiology, SSIMS & RC, Davangere, Karnataka, India.

Abstract : Giant-cell tumor constitutes 4-20% of all primary bone tumors in south east Asian population. They are benign locally aggressive bone tumour first described by cooper in 1818. These tumors occur predominantly in meta-epiphyseal region. Most often they are located around the knee joint. Although most of the tumors are diagnosed on plain radiograph alone, varying CT and MRI presentations of these tumors are essential to narrow down the differentials has an extended pre operative assessment .

Keywords: CT, Epiphysis, Giant cell tumour, MRI, Radiograph

I. Introduction

Giant cell tumor (GCT) of the bone is a benign, but locally aggressive and destructive primary bone tumour. Histopathology reveals its origin from three cell types- neoplastic giant cell tumour stromal cells (GCTSC), representing the proliferative fraction, secondarily recruited mononuclear histiocytic cells (MNHC) and multinuclear giant cells (MNGC)². GCT may account for 20% of all primary skeletal neoplasms¹. Generally occurring in skeletally mature individuals with its peak incidence in the third decade of life, less than 2% are found in patients with open epiphyses. There is a slight female predominance (56.4% in one large series). GCTs of the small bones of the hand and foot seem to occur at a slightly younger age group and demonstrate a higher incidence of multicentricity than that in other locations³. 5-10% can be malignant which may be Primary malignant or secondary malignant (sarcomatous change after radiotherapy). these tumours are typically monostotic ,occasionally multicentric(1%)⁴.

Location –Long bones(85%), Flat bones (15%), Distal Femur (30%), Proximal Femur(4%), Proximal Tibia(25%), Proximal Fibula(4%), Distal Radius(10%), Sacrum(4%), Proximal Humerus(8%), Iliac bone (3%), Distal Tibia(5%), Spine (3%), Hand and Wrist(5%), Foot(1%).

Although the tumor is benign, in 3.5% of patients they shows metastases to the lungs and more rarely to other sites

This pictorial review demonstrates a spectrum of radiological features of GCT involving lower limb.

II. Materials And Methods

2.1 CT Scanning Protocol

All patients underwent scanning with spiral CT scanner (Seimens Somatom Volume Zoom Plus 4 Multislice Spiral CT). The CT sections first were obtained without administration of IV contrast material [Slice width 1.0 mm-10 mm and Pitch 1-2].

2.2 MR Imaging Protocol

All patients had undergone MRI examinations with 1.5 Tesla on Philips Gyroscan Nova 1.5 Tesla MRI. Sequences used are

Conventional T₁W TSE [TR=600msec, TE=15 msec],

T₂W TSE [TR=3780msec, TE=100 msec] in multiple planes,

Fast spin echo sequences with fat suppression or short T₁ inversion recovery (STIR) sequences [TR=1500msec; TE=15msec],IV contrast was used in patients wherever required. Additional sequences were used as required. The findings of CT and MR are compared and correlated with histopathological / FNAC / biopsy / operative findings, whichever is available.

Radiographic Features

GCT is commonly located in the epiphysis with or without extension to metaphysis and frequently abuts the articular surface. Presents as an eccentric lytic lesion with narrow zone of transition but can also have a more aggressive appearance with ill-defined borders.

Early lesions are limited to the original bone contours. With growth, the tumor usually bulges beyond the confines of the cortex, which undergoes varying degrees of resorption. A significant percentage may cause eccentric or concentric cortical erosion and extend into soft tissues. Due to massive osteoclastic proliferation they give the appearances' of lobulations to the tumour.

2. Computed

Tomography It has an advantage of better delineation of the bony margins of the lesion and the status of the cortex including the adjacent articular cartilage invasion. However, it may suggest disruption of a thinned, but continuous cortex and therefore may be misleading. CT is superior to conventional radiography in outlining the extent of the tumor, especially its extra-osseous portion and its relationship to adjacent structures and determination of tumor recurrence. The presence or absence of matrix calcification can be evaluated. Fluid levels may be seen secondary to an aneurysmal bone cyst component or due to intratumoral hemorrhage. Reactive changes and edema on the outer cortical surface or the synovium may mimic tumor extension³. MPR and 3D images helps the surgeon in understanding the extent of tumour and anticipated surgical complexities.

3. Magnetic Resonance Imaging

MRI is currently is the imaging modality of choice for GCT because of its superior contrast resolution and multiplanar imaging capabilities that allow accurate tumor delineation. MRI is useful in determining extra-osseous extent and articular surface involvement, however subtle cortical destruction is better demonstrated by CT. GCT shows low intensity on T1W and heterogeneous high intensity on T2W images. Therefore intramedullary tumor is best seen on T1W, while its extra-osseous portion is best appreciated on T2W images^{5,6}. The hypervascular stroma contains sinusoidal vessels, which predispose to hemorrhage⁷.

The phagocytosed erythrocytes lead to iron deposition in the form of hemosiderin. GCT's often have extensive hemosiderin deposition within tumor tissue, resulting in very low signal intensity on all pulse sequences. This is seen in upto 60% of patients. Low signal areas may also be due to collagen deposition secondary to surgery or trauma⁸. Gadolinium enhancement reveals areas of hypervascularity and enhancement with a very heterogeneous signal pattern⁹.

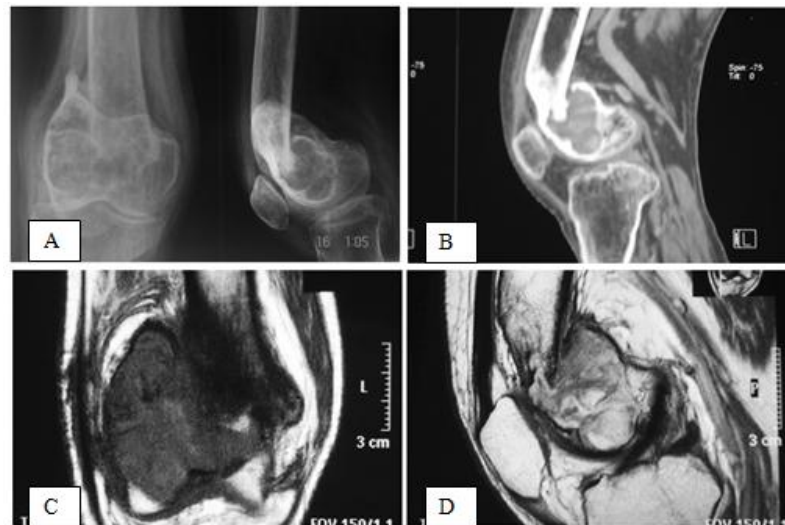


Fig 1.GCT Femur . (A) Radiograph-lytic lesion in lower end of femur with pathological fracture. (B)CT-there is thinning of cortex of femoral condyle with pathological fracture. (C)T1W coronal-homogenous hypointense tumor tissue with pathological fracture. (D)T1 WCE-the tumour tissue is homogeneously enhancing

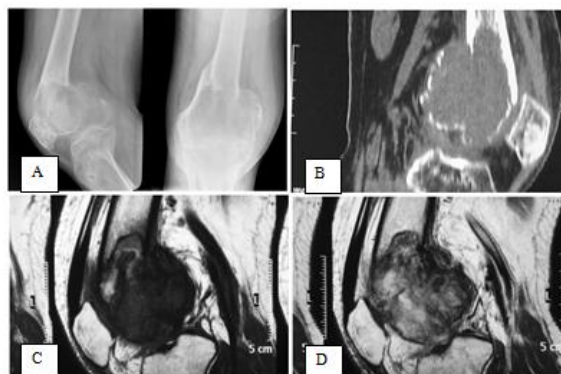


Fig2.GCT Femur. (A) Radiograph-expansile subarticular lytic lesion with thinning of cortex and pathological #. (B) CT-pathological fracture with thinning of cortex. (C) T1W SAG-hypointense lesion involving knee joint. (D) T1W CE heterogeneously enhancing tumor tissue with fracture of lower end of femur.

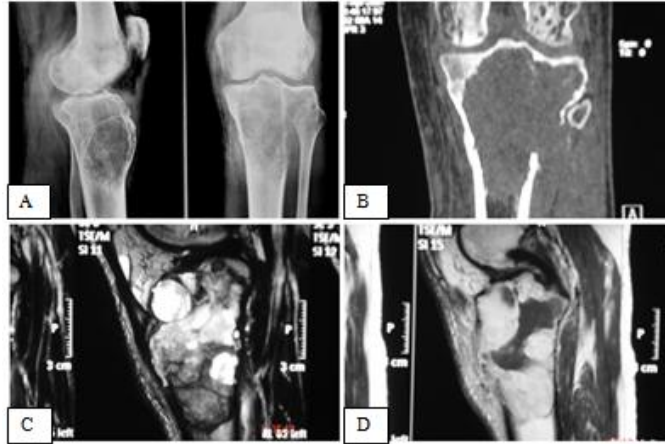


Fig.3.GCT Tibia. (A) Radiograph shows radiolucent lytic lesion in epiphysis in subarticular region with narrow zone of transition. (B) CT shows thinning of cortex with hypodense soft tissue. (C) T2W SAG- Heterogenous lesion with few hyperintense areas. (D) T1W CE SAG-Homogenous enhancement with central non enhancing area s/o necrosis.

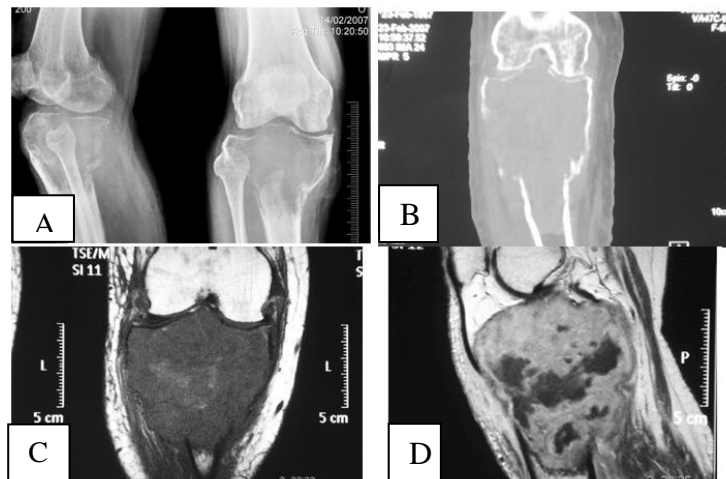


Fig 4.GCT Tibia. (A) Radiograph-expansile lytic lesion seen in the upper epiphysis of tibia. (B) CT-there is thinning of cortex seen. (C) T1W coronal-a hypointense lesion is seen. (D) T1W CE-homogenous enhancement seen with central hypointensity s/o necrosis.

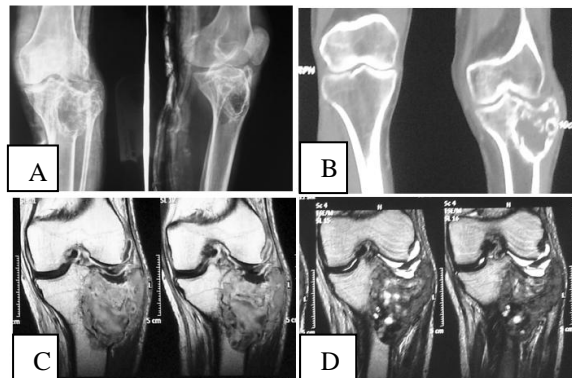

Fig 5.GCT Tibia. (A) Radiograph-an expansile , eccentric lytic lesion seen in upper tibial epiphysis. (B) CT-the lytic lesion has sclerotic margin with break in tibial plateau. (C)-T1W CE-there is homogenous enhancement of tumor tissue. (D)-T2W coronal-there is knee joint effusion –hyperintense signal.

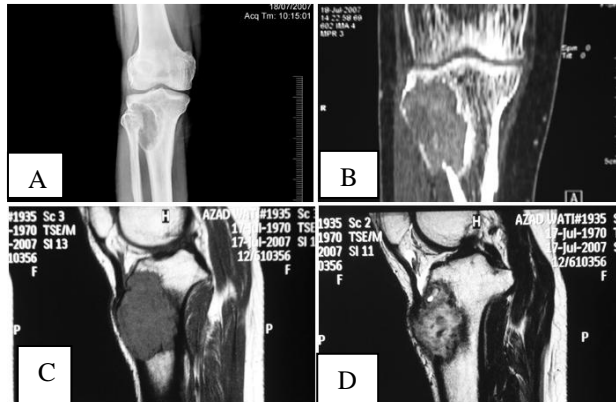

Fig 6.GCT Tibia. (A) Radiograph-an eccentric lytic lesion seen in the upper end of tibia. (B)CT-there is sclerotic margin with hypodense lesion. (C)T1W-hypointense lesion with narrow zone of transition seen. (D)T2W-heterogenous lesion with hypointense rim seen.

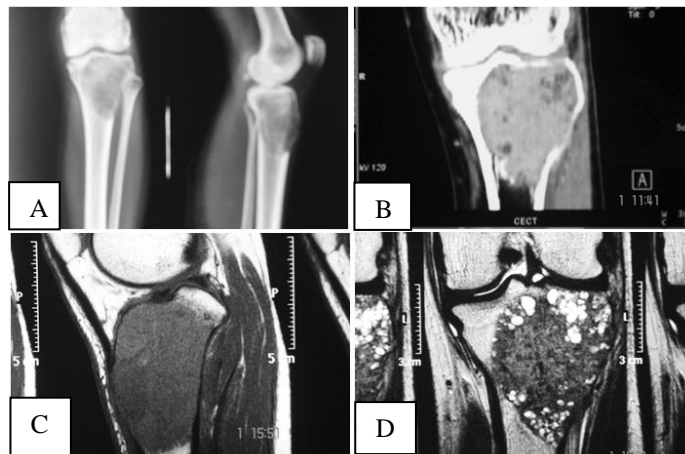


Fig 7.GCT Tibia. (A) Radiograph-a lytic lesion seen in epiphysis of tibia with scalloped margins. (B)CECT-a homogeneously enhancing lesion seen with thinning of cortex. (C)T1W Sag-homogenous hypointense lesion in epiphysis of tibia. (D)T2W coronal.-hypointense lesion with hyperintense areas with knee joint effusion.

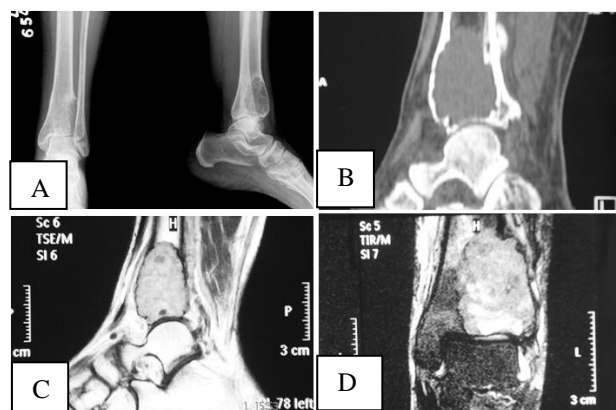

Fig 8. GCT Tibia. (A) Radiograph-a lytic lesion seen in epiphysis of tibia with trabecular pattern. (B)CT-subarticular lesion with thinning of the cortex seen.(C)T1W CE-homogenous enhancement of the lesion seen with hypointense rim.(D)STIR-the lesion is homogeneously hyperintense.

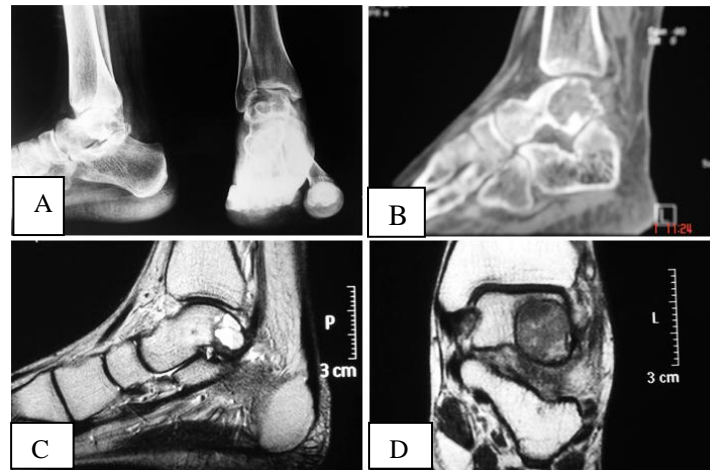


Fig 9. GCT Talus. (A)Radiograph-Radiolucent lytic lesion with sclerotic margins seen in talus. (B)CT-Lytic lesion with enhancing tumor tissue and thinning of cortex seen. (C)T2W SAG Hyperintense lesion with fluid levels seen in talus. (D)T1WCE Homogeneously enhancing lesion with hypointense rim seen in talus.

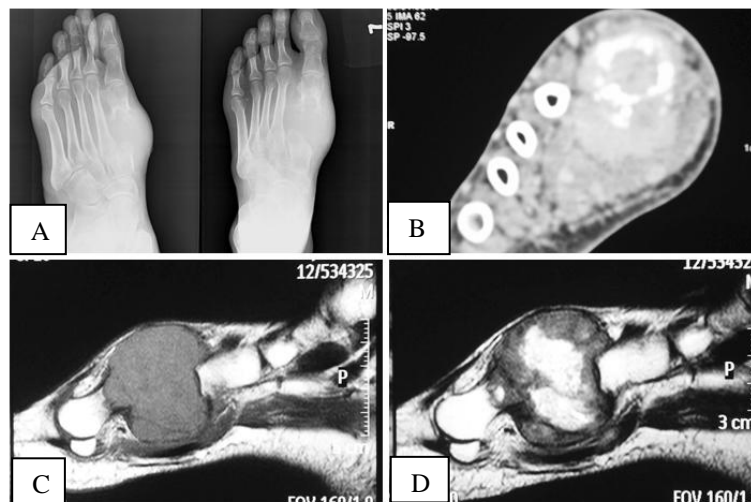


Fig 10. Malignant GCT Metatarsal.

(A)Radiograph-a lytic lesion with soft tissue density seen in proximal metatarsal region. (B)CT-a heterogeneously enhancing soft tissue component with destruction of the first metatarsal . (C)T1W SAG-a homogenous hypointense soft tissue seen replacing proximal part of metatarsal. (D) T2W SAG-the lesion has central hyperintensity with peripheral hypointensity. The first tarsometatarsal joint is involved.

III. Conclusion

Our histopathologically proved cases highlights the wide spectrum of radiological presentations of GCT in lower limb bones. The radiologist must be aware of its imaging features in order to differentiate it from other similar bone lesions such as Aneurysmal bone cyst, Brown tumor, Cartilaginous tumor (Chondroblastoma, Enchondroma) etc. Characteristic CT and MR features, together with clinical information, are a valuable diagnostic tool in offering a correct pre-operative diagnosis and treatment.

References

- [1]. Turcotte RE. Giant cell tumor of bone. Orthop Clin North Am 2006;37(1):35–51.
- [2]. M. (2006). Giant cell tumour of bone: morphological, biological and histogenetical aspects. Springer-Verlag , 30, 484-489.
- [3]. Pardiwala D N, Vyas S, Puri A, Agarwal M G. Pictorial essay : Giant cell tumor of bone. Indian J Radiol Imaging 2001;11:119-26
- [4]. Chakarun J Corey, et al. Giant Cell Tumor of Bone: Review, Mimics, and New Developments in Treatment. Radiographics. 2013 Jan-Feb;33:197-211.
- [6]. Hermann SD, Mesgarzadeh M, Bonakdarpour A, Dalinka MK. The role of magnetic resonance imaging in giant cell tumour of bone. Skeletal Radiol. 1987;16:635–43.
- [7]. Brady TJ, Gebhardt MC, Pykett IL, Buonanno FS, Newhouse JH, Burt CT, et al. NMR imaging of forearms in healthy volunteers and in patients with giant cell tumour of bone. Radiology. 1982;144:549–52.

- [8]. Aoki J, Moriya K, Yamashita K, Fujioka F, Ishii K, Karakida O, et al. Giant cell tumors of bone containing large amounts of hemosiderin: MR-pathologic correlation. *J Comput Assist Tomogr.*1991;15:1024–7
- [9]. 8). Aoki J, Tanikawa H, Ishii K, Seo GS, Karakida O, Sone S, et al. MR findings indicative of hemosiderin in giant-cell tumor of bone: Frequency, cause, and diagnostic significance. *AJR Am J Roentgenol.*1996;166:145–8.
- [10]. Resnick D, Kyriakos M, Greenway GD. Tumors and tumor-like lesions of bone: Imaging and pathology of specific lesions. In: Resnick D, Niwayama G, editors. *Diagnosis of bone and joint disorders.* Philadelphia: Saunders Company; 1988. pp. 3617–888.